



PATIENT

Chip Pham

SPECIES

Canine

BREED

Mix

SEX

Male Neutered

AGE

9 years

WEIGHT

44.1lbs

INTERPRETED BY

Maggie Machen Lamy,
DVM, DACVIM
(Cardiology)

IMAGING PERFORMED BY

Tom McNeill

HOSPITAL NAME

SVS Imaging CT

REFERRING VET

Animal Clinic of
Elkhorn

INVOICE

24716

DATE

6/10/22

PRESENTING CLINICAL SIGNS

History: History of coughing and tachypnea. Increased effort noted over the past 2 days. Grade 4/6 murmur.

-Radiographs: Revealed suspected congestive heart failure. Started on medication to treat. VHS 13.5 with perihilar pulmonary edema.

ECHOCARDIOGRAM FINDINGS

2D, m-mode, color flow and doppler imaging is available. Diffuse thickening of mitral valve leaflets with mild prolapse into the left atrial lumen. A ruptured chordae tendineae is visualized (see below). Marked eccentric mitral regurgitation with marked left atrial dilation. Normal MR velocity. Moderate LV dilation with hyperdynamic myocardial function. The tricuspid valve appears thickened with moderate TR. Velocity consistent with moderate pulmonary hypertension. Mild right heart enlargement. The pulmonic and aortic valves are normal in morphology and mobility. Normal aortic and pulmonic outflow velocities with laminar flow. No AI/PI. No pericardial or pleural effusion noted. No obvious cardiac masses.

CARDIAC CHART

CANINE CARDIAC PARAMETERS	MR VMAX (m/s)	TR VMAX (m/s)	LA/AO (Boon method)	LA/AO (Heart Base; Swe)	FS (%)	EF (%)	EPSS (cm)
NORMAL PARAMETER	4.5-5.5	<2.7	1.3	<1.6	28-40	40-100	<0.6
PATIENT	4.5	3.5	2.4	2.7	44	75	0.45
CANINE CARDIAC PARAMETERS	HR (BPM)	AV VMAX (m/s)	PV MAX (m/s)	BODY WEIGHT (kg)	LA 2D short axis Base view (cm)	LVIDd Avg; 2D and m-mode short axis (cm)	LVIDs Avg; 2D and m-mode short axis (cm)
NORMAL PARAMETER	50-100	0.7-1.7	0.7-1.6	BELOW	BELOW	BELOW	BELOW
PATIENT	180	1.2	0.7	20.0	4.6	5.4	3.2
*Normal chamber parameters expressed as a mean value (SD)				3	1.27 (5.3)	2.46 (2.46)	1.36 (5.5)
BODY WEIGHT DEPENDENT PARAMETERS				5	1.40 (4.5)	2.74 (5.2)	1.60 (4.7)
<i>*Note: All measurements based upon multi-modal images and methods. An average value is reported.</i>				10	1.50 (3.8)	3.27 (3.5)	2.06 (3.1)
				15	1.83 (2.0)	3.71 (2.4)	2.43 (2.1)
				20	2.02 (1.9)	4.14 (2.2)	2.80 (2.0)
				25	2.18 (2.4)	4.48 (2.9)	3.10 (2.5)
				30	2.33 (3.3)	4.83 (3.9)	3.39 (3.4)
				35	2.48 (4.3)	5.17 (5.0)	3.69 (4.5)
				40	2.62 (5.2)	5.48 (6.1)	3.96 (5.4)
				50	2.88 (7.1)	6.07 (8.3)	4.46 (7.4)

INTERPRETATION OF THE FINDINGS & FURTHER RECOMMENDATIONS

Chronic degenerative valve disease causing marked mitral and moderate tricuspid regurgitation. Marked left atrial enlargement indicates the risk for spontaneous congestive heart failure is elevated. A ruptured chord leading to a flail leaflet is visualized which dramatically raises this risk. Moderate pulmonary hypertension is noted, which is likely secondary to chronic LA pressure elevation and a reported cough. No additional issues are identified.

In light of the clinical signs, reported chest radiograph findings and severity of disease on echocardiogram, congestive heart failure is certainly present and continued cardiac medications

**PATIENT**

Chip Pham

SPECIES

Canine

BREED

Mix

SEX

Male Neutered

AGE

9 years

WEIGHT

44.1lbs

INTERPRETED BYMaggie Machen Lamy,
DVM, DACVIM
(Cardiology)**IMAGING
PERFORMED BY**

Tom McNeill

HOSPITAL NAME

SVS Imaging CT

REFERRING VETAnimal Clinic of
Elkhorn**INVOICE**

24716

DATE

6/10/22

are warranted lifelong as below. If the cough persists despite an increase in diuretic therapy, Hydrocodone should certainly be considered +/- a course of broad-spectrum antibiotic. Monitoring of sleeping respiratory rates will be paramount to screen for congestive heart failure at home. The average survival time of canine patients with active pulmonary edema is 8-9 months on medications, however they generally are able to maintain a good quality of life for that period. Patient will always be at risk for recurrent CHF, development of arrhythmias/LA tear, syncope and/or sudden death in the future.

Omega fatty acid supplementation and mild salt restriction may also be of some long-term benefit. Monitor for acute progression of the cough, labored breathing, exercise intolerance or collapse episodes in the future.

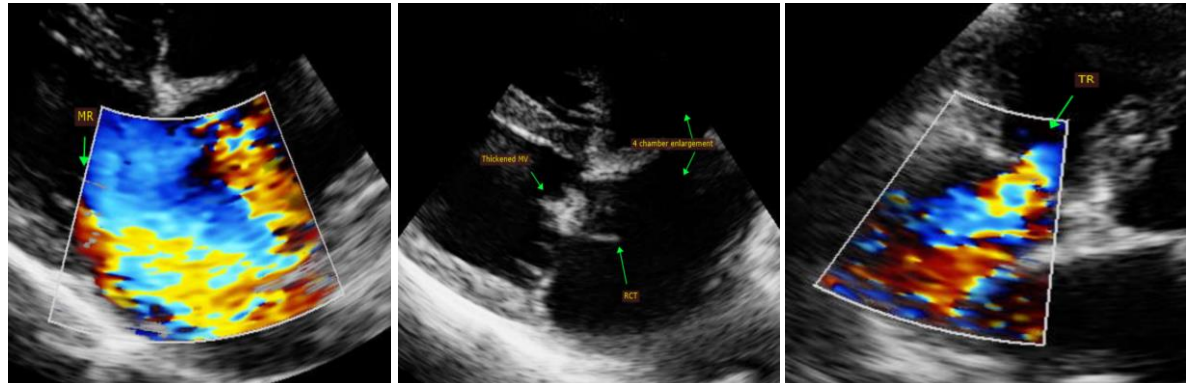
Avoid anesthesia, steroids and/or fluid therapy going forward.

PLAN

Administer Pimobendan as prescribed. Administer Furosemide to 1-2mg/kg PO q12h. Institute spironolactone 1-2mg/kg PO q12h.

Monitor SRRs at home. Monitor renal values and BP in 10-14 days, then every 3-4 months while on diuretics. If doing well and BP >130mmHg, administer ACEI to 0.5mg/kg PO q12h. Consider hydrocodone if needed for QOL +/- a course of broad-spectrum antibiotic.

Recommend conservative monitoring with a recheck echocardiogram in 6 months, sooner if any development of associated clinical signs occurs in the interim.

IMAGES

The information and recommendations provided are based on the images presented by the referring veterinarian. No evaluation can be communicated regarding pathology that was not visible in the image/video clips provided.

Thank you for this referral. If the clinical or image interpretation does not parallel your findings or if I can be of any further assistance, please contact me.

Maggie Machen Lamy, DVM
Diplomate of the American College of Veterinary Internal Medicine (Cardiology)
info@sonopath.com